

*Original Article*

# Evaluation of Brest cancer by two different modalities Ultrasound and Mammography

Asma Moktar Koshada

1.Faculty of Medicine, Alzaweya University

[a.Kushada@zu.edu.ly](mailto:a.Kushada@zu.edu.ly)

---

## ABSTRACT

---

Ultrasound is an inexpensive, simple test that doesn't cause any discomfort or anxiety from claustrophobia as an Mammography might. Ultrasound tests also don't emit any radiation, so they are safe for just about everyone. They also offer very clear images, better than those produced by an X-ray. Ultrasound can provide a more precise diagnosis than a mammogram alone and can better detect very small abnormalities and those in dense breasts. The main objective is the Confirmation of breast cancer by ultrasound, determined false negative by comparison with histopathology report and determined false positive by comparison with histopathology report. A hundred cases were present at oncology institute, they were divided in to tow group 50 were above 35y old and the other one younger than that, first group were examined by ultrasound and mammography, while the second group were examined by ultrasound only. The study showed that about 72% of cases were having malignancy by histopathology, while the other had malignancy by either ultrasound or mammography. 28 % were found to be benign case. In conclusion , the accuracy of breast cancer detection by ultrasound helps in decreasing waiting time for histopathological report. Therefore, ultrasound is found to be useful tool to evaluate high risk patient's especially in young ages.

Therefore, from this study we recommend both mammography and ultrasound are often used together to improve breast cancer detection and diagnosis.

---

**Key words:** Ultrasound , Mammography, Histopathology, Oncology

---

**Citation:** Moktar Koshada Asma . Evaluation of Brest cancer by two different modalities  
Ultrasound and Mammography Population 2023;17(2):31/12/2023. <https://doi.org/10.26719/LJM17-2.14>

**Received:** 03/11/23; **accepted:** 10/12/23; **published:** 31/12/23

Copyright ©Libyan Journal of Medical Research (LJMR) 2023. Open Access. Some rights reserved. This work is available under the CC BY license <https://creativecommons.org/licenses/by-nc-sa/3.0/igo>

## Introduction

Breast cancer is a significant health concern affecting women worldwide. Early detection plays a crucial role in improving the chances of successful treatment and survival. Two commonly used imaging techniques for breast cancer detection are ultrasound and mammography.

Mammography is a low-dose X-ray imaging technique specifically designed to examine the breast tissue<sup>1</sup>. It is the primary screening tool for breast cancer and has been used for several decades. Mammograms can detect small abnormalities, such as microcalcifications or masses, before they are even palpable. The procedure involves compressing the breast between two plates to obtain high-resolution images. Radiologists analyze these images for signs of abnormalities, such as suspicious masses or architectural distortions<sup>2</sup>.

Ultrasound, on the other hand, uses high-frequency sound waves to generate images of the breast tissue. It is often used as a complementary tool to mammography, particularly for further evaluation of suspicious findings or for imaging dense breasts<sup>3</sup>. During an ultrasound examination, a gel is applied to the breast, and a transducer is moved over the skin to capture images. The images provide detailed information about the characteristics of a mass, such as its shape, size, and vascularity.

Both ultrasound and mammography have their advantages and limitations in breast cancer detection. Mammography is highly

effective in detecting microcalcifications and small masses, particularly in women with fatty breasts<sup>4</sup>. However, it may be less sensitive in women with dense breast tissue, as dense tissue can mask abnormalities. Ultrasound, on the other hand, is useful in evaluating palpable masses and distinguishing between solid masses and fluid-filled cysts. It is also valuable for guiding needle biopsies<sup>3</sup>.

In many cases, both ultrasound and mammography are used together to improve breast cancer detection rates. This approach reduces the likelihood of missing abnormalities and provides a more comprehensive evaluation. Additionally, other imaging techniques such as magnetic resonance imaging (MRI) may be employed in specific situations to further assess the extent of the disease or in high-risk individuals<sup>5</sup>.

It's important to note that the interpretation of these imaging modalities requires expertise, and results should be evaluated by trained radiologists. Regular breast cancer screenings, including mammograms and, if necessary, ultrasounds, are recommended as part of a comprehensive approach to breast cancer detection and prevention.

**Experimental Protocol :**

One hundred cases were collected for researches were suspected as malignant cases after consent from the patient at Oncology Institute.

After verbal consent of patient history was taken from them and then they examine them.

- If the patient age above. <35y> she will go for mammography and ultra sound.
- Other young age from 20 to 35 will do ultra sound only.

Almost cases had biopsy under ultra sound guided biopsy then follow histopathology report .

**Image interpretation**

Using ultrasound criteria a lesion can be classified into a BIRADS-US system developed by the ACR6 with the following interpretation as shown in table-1:

- BIRADS-0: Incomplete assessment needs additional evaluation
- BIRADS-1: Normal
- BIRADS-2: Benign
- BIRADS-3: Probably benign (2% of less chances of malignancy)
- BIRADS-4: Suspicious (2-95% chances of malignancy)
- BIRADS-5: Malignant (>95% chances of malignancy)
- BIRADS-6: Biopsy-proven malignancy.

**Table-1 BIRAD Calcification Using Ultrasound Criteria**

BIRADS	Conditions that fall into the	Management
<b>BIRADS-1</b>	Normal tissue, focal thickening causing “lump”	Routine screening
<b>BIRADS-2</b>	Simple cysts, ductal ectasia, intramammary nodes, lipomas	Early follow-up to document stability unless clinical indications suggest a more aggressive evaluation
<b>BIRADS-3</b>	Complex cysts, small intraductal papillomas, fibroadenomas	Short interval follow-up or biopsy
<b>BIRADS-4</b>	One feature of malignancy	Biopsy
<b>BIRADS-5</b>	More than one feature of malignancy	Biopsy

**Results and Discussion:**

Table-2 : shows the relation between ultrasound report and histopathology report for women older than 35y.

NO	SEX	ULTRASOUND REPORT	HISTOPATHOLOGY REPORT
5	F	Distinct, irregular, central tumor mass with edematous tissue.	Inflammatory breast cancer
25	F	Large , coarse, irregular outlined, dense with calcifications	Carcinoma of the breast
3	F	Single or multiple, small, ring-like calcifications. Typically dense, uniform calcification in the periphery with a lucent center.	Fat necrosis
7	F	Ill-defined mass with heterogenous texture	Abscess
6	F	irregular tumor mass	Metastases other cancer
4	F	Ill-defined mass with heterogenous texture	Lost follow up

These data was represented by this charts as seen below.

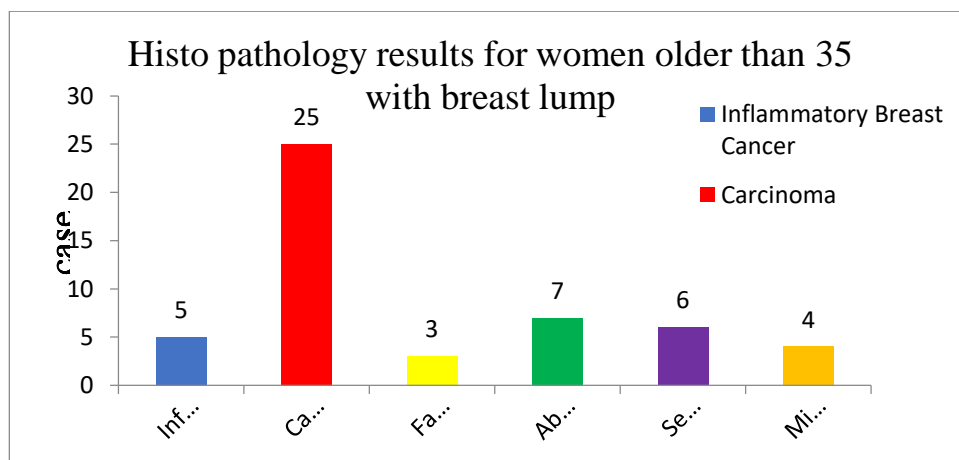


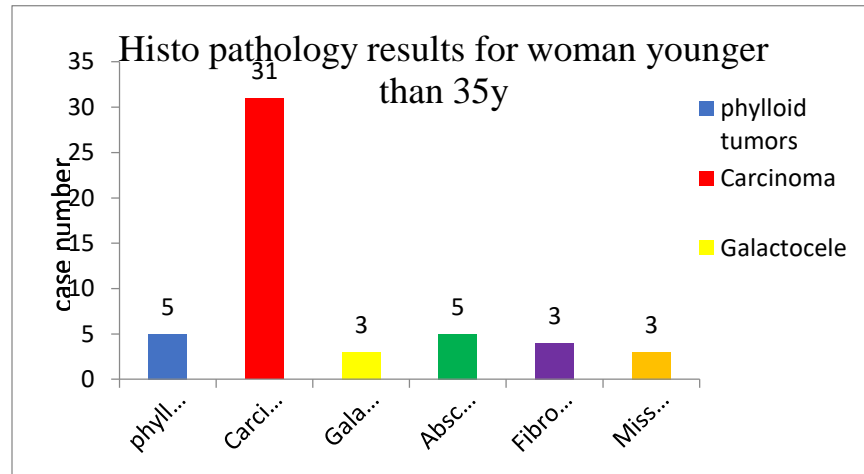
FIG4.1 shows the histopathology results for women older than 35 with breast lump, as 5 cases were inflammatory breast cancer ,25 cases were carcinoma, 6 cases were

secondary to other tumors, and other cases were benign lesion as fat necrosis, abscess.4 cases were missed.

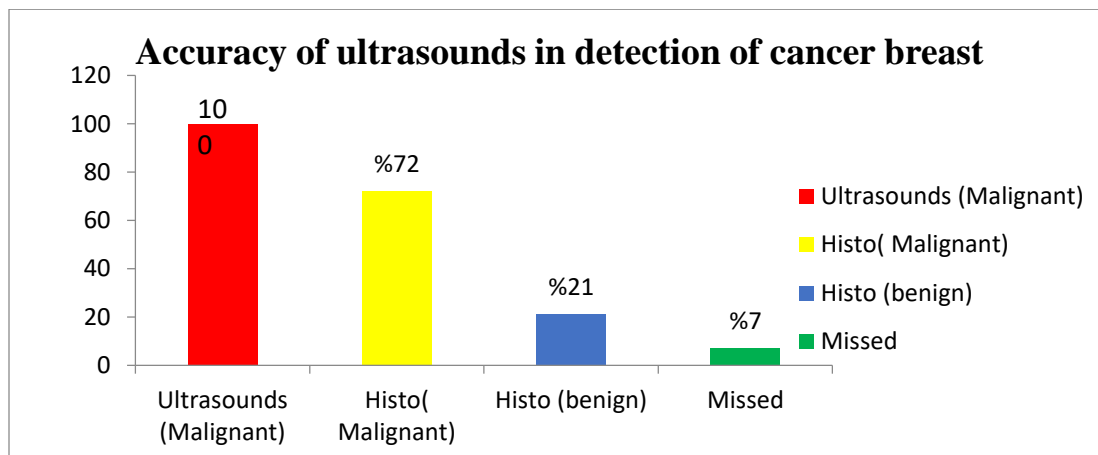
**Table-3 : Shows the relationship between ultrasound report and histopathology report in cases younger than 35y.**

NO	SEX	ULTRASOUND REPORT	HISTOPATHOLOGY REPORT
5	F	Distinct, irregular, central tumor mass from which dense spicules radiate in all directions.	Phyllodes cancer
15	F	This irregular hypoechoic mass with acoustic shadowing and an echogenic halo is typical of a carcinoma	Carcinoma of the breast
3	F	Single or multiple, small, ring-like calcifications. Typically dense, uniform calcification in the periphery with a lucent center.	Galactocele
5	F	Ill-defined mass with heterogonous texture	Abscess
16	F	Irregular tumor mass) Small echogenic foci of micro calcification associated with malignant lesions may be identified	Invasive ductal carcinoma
3	F	Ill-defined mass with heterogonous texture	Fibro cystics disease
3	F	Lost follow up	

These data was represented by this charts as seen below.



**Fig 4. Shows the histopathology results for women younger than 35 with breast lump, it can be seen 5 cases were phyllode breast cancer ,31 cases were carcinoma, and other cases were benign lesion as galactocele, abscess and fibrocystic disease.3 cases were missed.**



**Fig -5 Show the accuracy of ultrasound detection is 72%.**

### Conclusion

The study showed that about 72% of cases were found to have malignancy by histopathology were had finding of malignancy by ultrasound examination .were 21% have benign pathology by

histopathology had finding of malignancy by radiology work up. So using of ultrasound to raising the level of accuracy diagnosis of cancer breast and to decreased time waiting

histopathology report also to evaluate high risk patients young age by ultrasound.

Infection and inflammatory processes in the breast can be mistaken for malignancy on mammography and ultrasound. Breast abscesses are typically encountered in young lactating women. Inflammation in a no lactating breast is a more worrying feature, although infections and more unusual inflammatory conditions such as

### **Recommendation.**

1. Mammography is primarily a screening and not a diagnostic tool. The mediolateral oblique and craniocaudal views are standard screening views.
2. Ultrasound is a useful tool in diagnosis suspected cases and the local staging of breast cancer preoperatively. It tends to be a better predictor of tumors size than mammography and may detect intraductal tumor extension. Ultrasound may also detect small satellite tumor foci not visible on mammography.
3. There are characteristic malignant features on ultrasound modality image as follows :
  - Carcinomas are seen as well-defined masses and are markedly hypoechoic compared to the surrounding fat
  - Carcinomas tend to be taller than they are wide (the anterior to posterior dimension is greater than the transverse diameter).

granulomatous mastitis can occur. Skin erythematic and edema may be caused by an underlying carcinoma, termed 'inflammatory carcinoma'. In this situation, skin thickening and edema may be the only signs of malignancy recognized on the mammogram. In any case of unexplained inflammation, or when infection fails to resolve, percutaneous biopsy is required to make the diagnosis or exclude malignancy.

- There may be an ill-defined echogenic halo around the lesion, particularly around the lateral margins, and distortion of the adjacent breast tissue may be apparent, analogous to spiculation on the mammogram.
- Posterior acoustic shadowing is frequently observed, due to a reduction in the through transmission of the ultrasound beam via dense tumour tissue.
- Poorly differentiated, high-grade tumors' are more likely to be well defined, without acoustic shadowing .hence the importance of carrying out a biopsy of solid masses even when the ultrasound appearances are benign.
- Micro calcifications are sometimes observed, associated with high-grade tumours arising in areas of

DCIS6, although this is less frequently encountered than with mammography. Lobular carcinomas can be difficult to demonstrate on ultrasound. They may produce vague abnormalities, such as subtle alterations in echotexture, or the ultrasound findings may even be normal.

4. Doppler examination of malignant masses may show abnormal vessels that are irregular and centrally penetrating. In contrast, benign lesions such as fibroadenomas tend to show displacement of normal vessels around the edge of a lesion.
5. It has long been recognized that involvement of axillary lymph nodes is one of the most important prognostic factors for women with breast cancer. Traditionally, the axilla has been staged at the time of surgery by lymph node sampling procedures, sentinel node biopsy, or

clearance of the axillary lymph nodes. Surgical clearance of axillary lymph nodes is probably the 'gold standard';<sup>7</sup> however, it carries the risk of significant postoperative morbidity, with some women developing disabling lymphoedema in the arm. Ultrasound can identify abnormal nodes preoperatively that can then be biopsied percutaneously under ultrasound guidance<sup>8-9</sup>, allowing a preoperative diagnosis of lymph node involvement to be made in just over 40% of patients who are lymph node positive. This enables the more radical axillary clearance to be targeted to those patients with a preoperative diagnosis of axillary disease, with the sampling or sentinel node procedures reserved for those patients with a much lower risk of axillary involvement<sup>9</sup>.

## References:

1. W, Basset MC, Mahoney S, et al. *ultrasound Imaging*. 1st. Philadelphia, PA: Saunders; 2006.
2. The Breast. In: Rumack CM.1998 *Diagnostic Ultrasound*.
3. Stavros AT. The Breast. In: Rumack CM. *Diagnostic Ultrasound*. 4. Philadelphia, PA: Elsevier Mosby; 2011:773-839/20.
4. Sickles EA: Wild, J.J. and D. Neal. Use of high-frequency ultrasonic waves for detecting changes of texture in living tissues. *lancet*.2008;1:655-7
5. Dempsey, P. J. The history of breast ultrasound. *J Ultrasound Med*. July 2001;23:887-94.
- 6- Smith RA, Saslow D, Sawyer KA, et al. American Cancer Society guidelines for breast cancer screening: Update 2003. *CA Cancer J Clin*. 2003;53:141-169.



- 7- Wolfe JN: A study of breast parenchyma by mammography in the normal woman and those with benign and malignant disease. *Radiology* 1967; 89:201-205.
- 8- Ellis IO, Galea M, Broughton N, et al: Pathological prognostic factors in breast cancer. II. Histological type. Relationship with survival in a large study with long-term follow-up. *Histopathology* 1992; 20:479-489.
- 9- Lampejo OT, Barnes DM, Smith P, et al: Evaluation of infiltrating ductal carcinomas with a DCIS component: correlation of the histologic type of the in-situ component with the grade of the infiltrating component. *Semin Diagn Pathol* 1994; 11:215-222.