Libyan Journal of Medical Research

www.ljmr.ly/ eISSN:2413-6096

Original Article

DOI: https://doi.org/10.54361/LJMR.20.1.02

Avian Haemosporidium Effects on some blood parameters of free range chickens.

Nagia A. S. Abdalsalam[1], **Hana. A. Ali**[2], **Ahmad, Boulabyidh**[2]

[1]Department of Pathology and Clinical Pathology, Faculty of Veterinary Medicine, Omer AL-Mukhtar University, Libya.

[2] Department of Parasitology, Faculty of Veterinary Medicine, Omer AL-Mukhtar University, Libya.

Corresponding Author, *Nagia A. S. Abdalsalam*, Nagia.abdalsalam@omu.edu.ly

Abstract

Background: Avian hemoparasites pose a major risk to poultry farming in North African nations; however, there is limited information on their prevalence and effects in Libya.. **Objective:** This research aimed to assess the occurrence of blood parasites in domestic chickens across Libya and to analyze their influence on complete blood count (CBC) and bilirubin levels. **Materials and Methods**: A total of 50 domestic chickens were studied, collected from different regions of Libya. Blood samples were taken and analyzed using the Giemsa staining method for parasite detection. Hematological parameters, including red blood cell (RBC) count, white blood cell (WBC) count, hemoglobin, and packed cell volume (PCV), along with total bilirubin levels, were recorded. The chickens were divided into infected (n=27) and non-infected (n=23) groups. Results: Microscopic analysis identified three types of hemoparasites: Leucocytozoon spp. (11.1%), Haemoproteus spp. (18.5%), and Plasmodium spp. (14.8%). Infected chickens exhibited a marked decrease in RBC count (2.1±0.4 vs 2.9±0.5 $\times 10^6/\mu L$, $p<0.01$), hemoglobin levels (9.2±1.8 vs 11.8±2.1 g/dL, $p<0.01$), and PCV (24.3±4.2 vs 31.5±5.1%, $p<0.01$) when compared to non-infected ones. Moreover, total bilirubin levels rose significantly in infected chickens (0.68±0.15 vs 0.32±0.08 mg/dL, $p<0.001$), and the WBC count was higher in the infected group (23.4±3.2 vs 16.8±2.5 $\times 10^3/\mu L$, $p<0.01$). **Conclusion:** Blood parasites are widespread among domestic chickens in Libya, leading to significant changes in hematological parameters such as anemia and elevated bilirubin levels. These findings suggest a potential negative impact on poultry health and productivity.

Keywords: Leucocytozoon, Haemoproteus, Plasmodium, hematology, bilirubin, chickens, Libya

Introduction

Poultry production serves as a cornerstone of food security and rural livelihoods across developing nations, with domestic chickens representing the most widely distributed avian species globally [1]. In Libya, backyard poultry farming constitutes an integral component of the agricultural economy, providing essential protein sources and income generation for rural communities. However, parasitic diseases continue to impose substantial constraints on productivity, with blood parasites emerging as particularly insidious pathogens due to their subtle clinical presentation and chronic debilitating effects [2]. Avian hemoparasites, primarily belonging to the genera Plasmodium, Haemoproteus, and Leucocytozoon, represent protozoan parasites transmitted by hematophagous arthropod vectors, including mosquitoes, hippoboscid flies, and simuliid blackflies [3]. These parasites exhibit worldwide distribution, with particular prevalence in tropical and subtropical regions where favorable environmental conditions support vector populations [4]. While acute mortality events remain relatively uncommon, chronic infections induce significant physiological stress, immunosuppression, and reproductive impairment, ultimately compromising host fitness and population dynamics [5]. The pathophysiological consequences of hemoparasite infections manifest predominantly through hematological alterations. Intracellular parasitism of erythrocytes leads to hemolytic anemia characterized by reduced red blood cell counts, diminished hemoglobin concentrations, and decreased packed cell volume [6]. The destruction of infected erythrocytes triggers hemoglobin catabolism, resulting in elevated bilirubin production as a metabolic byproduct. This hyperbilirubinemia serves as a valuable diagnostic marker, correlating with infection severity and hemolytic activity [7]. Furthermore, parasitic infections stimulate host immune responses, manifesting as leukocytosis with heterophilia and lymphocytosis, reflecting the organism's attempt to combat the parasitic burden [8]. Despite extensive research on avian hemoparasites in other geographical regions, epidemiological data from North African countries, particularly Libya, remain markedly deficient. The unique ecological conditions of Libya, characterized by Mediterranean coastal zones transitioning to arid inland regions, create distinctive epidemiological patterns potentially favoring specific parasite-vector complexes. Understanding the prevalence and pathological impact of these parasites in Libyan domestic chickens represents a critical gap in veterinary parasitology knowledge, with direct implications for disease management strategies and poultry productivity enhancement. Therefore, this

Received: 09-11-2025-*Accepted:* 04-01-2026 -*Published:* 07-01-2026

DOI: https://doi.org/10.54361/LJMR.20.1.02

investigation was designed to address these knowledge deficits through a comprehensive assessment of blood parasite prevalence in domestic chickens across Libyan regions, employing classical microscopic techniques for parasite identification. Additionally, this study aimed to quantify the hematological and biochemical consequences of parasitic infections through a comparative analysis of complete blood count parameters and bilirubin levels between infected and non-infected populations. The generated data will provide valuable baseline information for veterinary practitioners, inform control strategies, and contribute to the broader understanding of avian hemoparasite epidemiology in North African ecosystems.

Materials and Methods

1. Ethical Approval

This study received ethical approval from the Al-Mukhtar Committee for Bio-safety and Bioethics at Omar Al-Mukhtar University (NBC: 007. H 25 55).

1.2. Sample Size and Study Design

Sample size calculation was based on expected parameters (σ = 1.5 g/dL,d = 1.0 g/dL), 50 chickens were recruited to ensure adequate statistical power while accounting for potential attrition.

1.3. Animals

Between June and August 2025, 50 adult chickens (1-3 years, mixed sex) were obtained from local breeders and housed at Omar Al-Mukhtar University Veterinary Clinic.

1.4. Blood Sample Collection

Following physical restraint, 3 mL of blood was aseptically collected from each bird via brachial wing vein venipuncture using sterile 21-gauge needles and disposable syringes. Blood samples were immediately partitioned into two aliquots: 1.5 mL transferred into EDTA-containing vacuum tubes for hematological analysis and blood parasite screening, and 1.5 mL dispensed into plain tubes without anticoagulant for serum biochemistry. Thin blood smears were prepared immediately from the EDTA-anticoagulated blood for microscopic examination of hemoparasites. All samples were labeled with unique identification codes, maintained at 4°C during transportation, and processed within 4 hours of collection to preserve cellular integrity and minimize artifacts.

1.5. Parasitological Examination: Giemsa Staining Technique

Thin blood smears were prepared immediately upon sample collection using standard methodology. A small drop of whole blood was placed on clean, grease-free glass slides and spread uniformly using a spreader slide at a 30-45° angle. Smears were air-dried for 10 minutes at room temperature, then fixed in absolute methanol for 5 minutes. After fixation, slides were stained using 10% Giemsa stain solution (pH 7.2, prepared by diluting commercial Giemsa stock with phosphate buffer) for 30 minutes according to protocols described by Valkiūnas [2]. Following staining, slides were gently rinsed with distilled water, air-dried, and examined under light microscopy. Initial screening was performed at 400× magnification to identify potential parasites, followed by detailed morphological examination at 1000× magnification under oil immersion. Parasite identification was based on morphological characteristics including size, shape, pigment distribution, and host cell preference, using reference atlases by Taylor et al. [22] and Atkinson and Van Riper [7]. Each slide was examined for a minimum of 15 minutes, scanning at least 100 microscopic fields before declaring negative results. Parasitemia intensity was semi-quantitatively graded as low (+), moderate ( ), or high (+) based on parasite density per 1000 erythrocytes.

1.6. Hematological Analysis (Complete Blood Count)

Blood samples were collected from the wing vein into a clean test tube containing EDTA for plasma, and then it was labeled and sent to the laboratory. Using the Automated Hematology Analyzer (Mindray), blood parameters, RBC, HB, PCV, MCV, MCH, MCHC, and WBC were examined.

1.7. Biochemical Analysis: Bilirubin Measurement

Serum was separated by centrifugation at 3000 rpm for 10 minutes and stored at -20°C until analysis. Total bilirubin concentration was quantified using the diazo method (modified Jendrassik-Grof technique) with a semi-automated biochemistry analyzer (Mindray BS-200®, China).

1.8. Statistical analysis:

All data were entered into Microsoft Excel 2019 and subsequently analyzed using IBM SPSS Statistics version 26.0 (IBM Corp., Armonk, NY, USA). Descriptive statistics, including means, standard deviations, and frequency distributions, were calculated for all variables. Chickens were categorized into two groups based on parasitological findings: infected (parasite-positive, n=27) and non-infected (parasite-negative, n=23). Normality of continuous variables was assessed using the Shapiro-Wilk test (p>0.05 indicating normal distribution). For normally distributed data, an independent samples t-test was employed to compare means between infected and non-infected groups. Variables demonstrating non-normal distribution were analyzed using the Mann-Whitney U test as a non-parametric alternative. Chi-square test or Fisher's exact test (when expected cell frequencies <5) was utilized for categorical variables, including parasite species prevalence across regions. Statistical significance was established at α=0.05 (two-tailed), with 95% confidence intervals calculated for all group comparisons. Effect sizes were reported using Cohen's d for t-tests (small: 0.2-0.5, medium: 0.5-0.8, large: >0.8) to quantify the magnitude of differences beyond statistical significance. Results are presented as mean ± standard deviation (SD) unless otherwise specified.

Results

Received: 09-11-2025-Accepted: 04-01-2026 -Published: 07-01-2026

DOI: https://doi.org/10.54361/LJMR.20.1.02

Prevalence of Blood Parasites

Microscopic examination of Giemsa-stained blood smears revealed hemoparasite infection in 27 out of 50 examined chickens, yielding an overall prevalence of 54.0% (95% CI: 39.3-68.2%). Three distinct genera of avian hemoparasites were identified based on morphological characteristics (Figures).

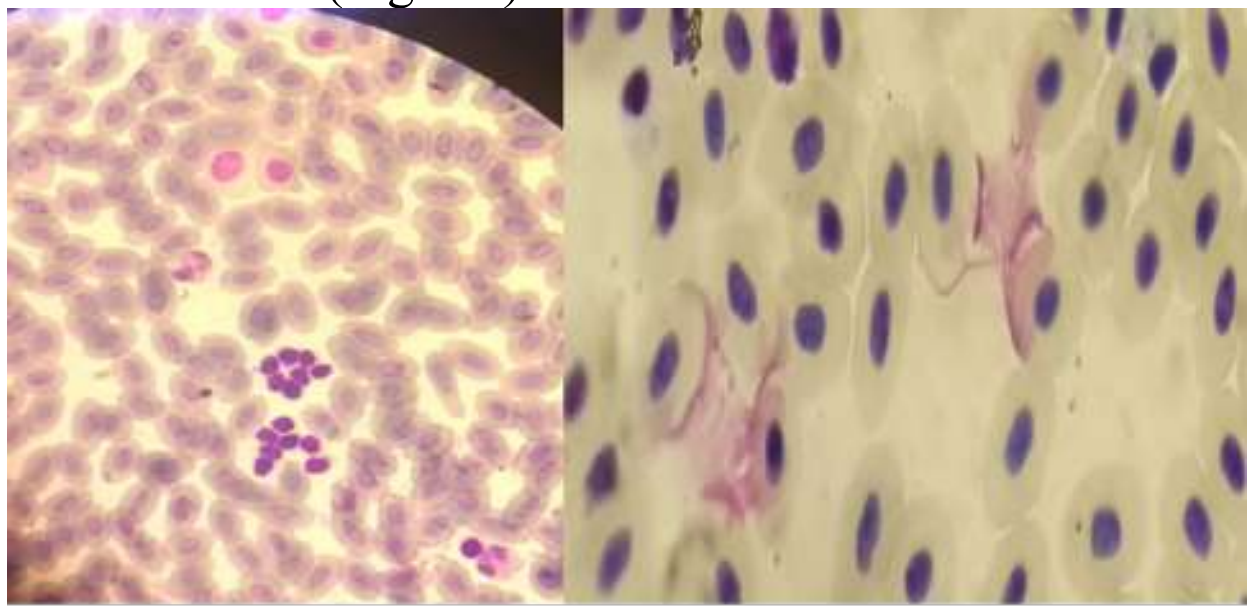

Figure 1:Photomicrographs of Blood Parasites in Domestic Chickens (Giemsa stain, 1000×).(A) The microscopic examination of this peripheral blood smear reveals cellular alterations highly characteristic of a Leucocytozoon infection, primarily evidenced by significant host cell hypertrophy where infected cells are markedly enlarged compared to the surrounding normal, nucleated erythrocytes. These enlarged cells exhibit distinct nuclear displacement, as the developing parasite occupies the majority of the cytoplasm and pushes the host cell's nucleus toward the periphery, often distorting it into a crescent or ribbon-like shape. Furthermore, the dense, "grape-like" clusters of deeply stained nuclei can be interpreted as an aggregation of infected cells or a massive inflammatory response consisting of thrombocytes and reactive leukocytes reacting to high parasitemia.(B) Microscopic view of avian blood infected with Leucocytozoon. Note the contrast between the normal oval nucleated erythrocytes and the significantly altered infected cells."

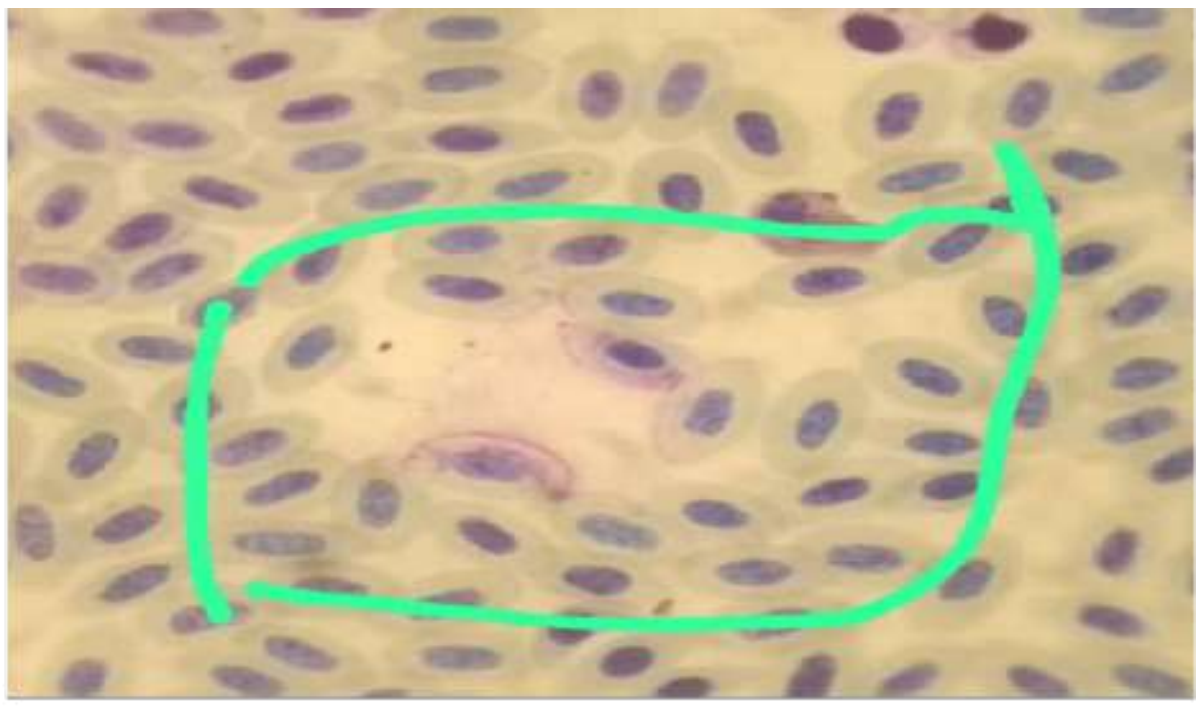

Figure 2: Microscopic examination of a Giemsa-stained avian blood smear revealing a hemoparasitic infection. The image demonstrates nucleated erythrocytes presenting with Haemoproteus spp. are evident, showing pigmented gametocytes that typically wrap around the nucleus in a characteristic "halter-shape" without significant nuclear displacement

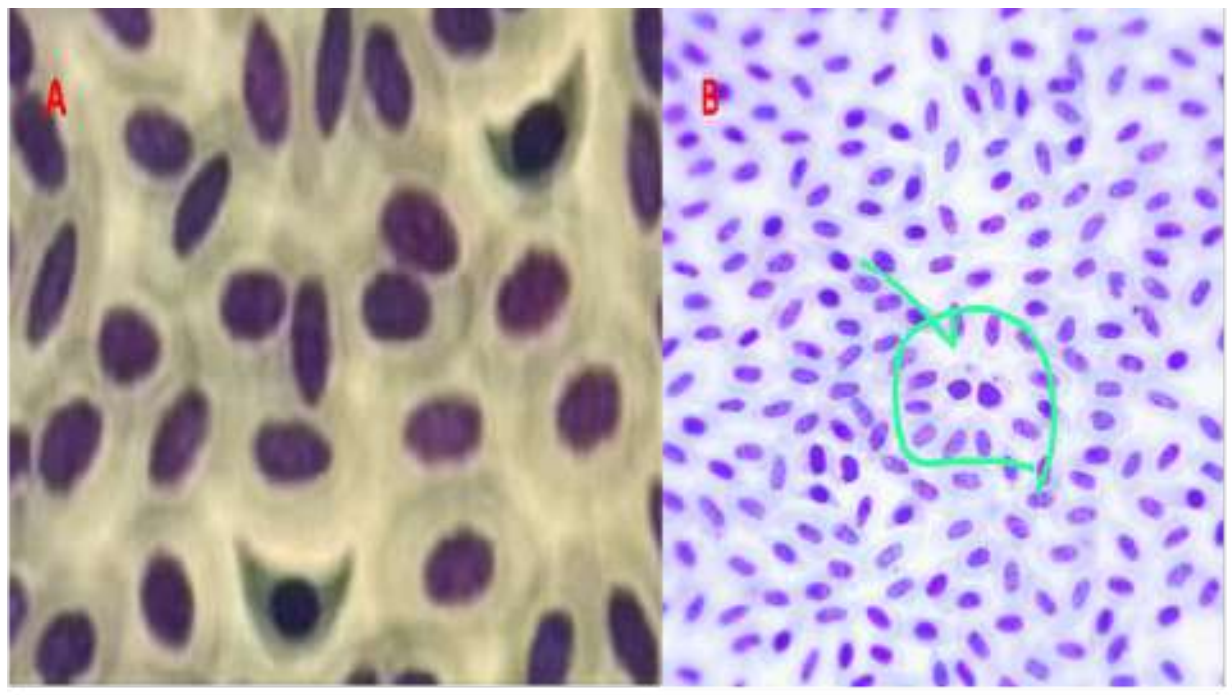

Figure3: Avian blood smear (Giemsa stain). Plasmodium spp. (Avian Malaria): (A) The image clearly demonstrates an erythrocyte containing a schizont. This stage is characterized by multiple nuclear divisions (merozoites) within the cytoplasm, a hallmark of Plasmodium that distinguishes it from other hemoparasites. (B) The smear reveals several nucleated erythrocytes containing intracellular parasites. Marked Area (Green Circle): Highlights an erythrocyte undergoing multiple fission, consistent with a Schizont stage of Plasmodium. This stage is characterized by the presence of multiple merozoites within the host cell's cytoplasm, often displacing or distorting the host nucleus.

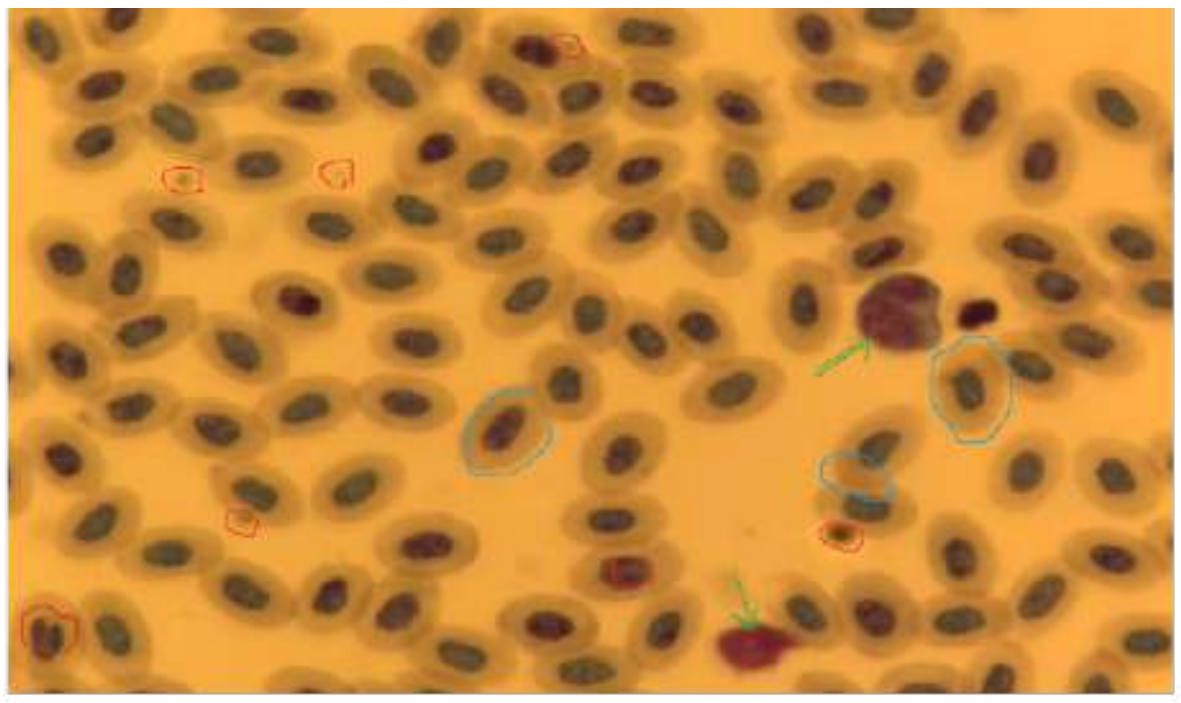

Figure 4: Microscopic examination of an avian blood smear (Giemsa stain) showing suspected hemoparasites. The image displays numerous nucleated avian erythrocytes (red blood cells). Several cells exhibit intracellular inclusions suggestive of parasitic infection: Red Circles (Suggestive of Plasmodium spp.): Point to erythrocytes containing small, distinct, dark, ring-like trophozoites within the cytoplasm, separate from the host cell nucleus. These forms are characteristic of early-stage avian malaria (Plasmodium). Blue Circles (Suggestive of Haemoproteus spp.): Indicate erythrocytes with perinuclear inclusions or pigmentation. While distinct gametocytes fully partially encircling the nucleus are not definitively seen at this magnification, these areas represent possible early developmental stages of Haemoproteus.Green Arrows: Indicate normal avian leukocytes (Lymphocytes).

Comparative Hematological Parameters

Table 1 presents comprehensive hematological profiles comparing infected and non-infected chicken groups. Infected chickens demonstrated significantly reduced erythrocytic parameters indicative of moderate normocytic normochromic anemia. Red blood cell count was markedly decreased in infected birds (2.1±0.4 $\times 10^6/\mu L$) compared to non-infected controls (2.9±0.5 $\times 10^6/\mu L$; t=6.58, $p<0.001$, Cohen's d=1.88), representing a 27.6% reduction. Similarly, hemoglobin concentration was significantly lower in infected chickens (9.2±1.8 g/dL) versus non-infected birds (11.8±2.1 g/dL; t=5.12, $p<0.001$, Cohen's d=1.46), indicating a 22.0% decrease. Packed cell volume followed an identical pattern, with infected birds exhibiting 24.3±4.2% compared to 31.5±5.1% in controls (t=5.89, $p<0.001$, Cohen's d=1.68). Erythrocyte indices revealed normocytic characteristics, with no significant differences in mean corpuscular volume between groups (infected: 115.2±12.4 fL; non-infected: 108.7±10.9 fL; t=1.98, p=0.053). However, mean corpuscular hemoglobin was marginally elevated in infected chickens (43.8±5.6 pg vs 40.7±4.8 pg; t=2.15, p=0.037), while mean corpuscular

Received: 09-11-2025-*Accepted:* 04-01-2026 -*Published:* 07-01-2026

DOI: https://doi.org/10.54361/LJMR.20.1.02

hemoglobin concentration showed no significant variation (38.0±3.2 g/dL vs 37.4±2.9 g/dL; t=0.71, p=0.482). Leukocyte parameters demonstrated marked elevations in infected birds, consistent with immune activation. Total white blood cell count was significantly higher in infected chickens (23.4±3.2 ×10^3/μL) compared to non-infected birds (16.8±2.5 ×10^3/μL; t=8.45, p<0.001, Cohen's d=2.41), representing a 39.3% increase. Differential counts revealed significant lymphocytosis in infected birds (12.8±2.4 ×10^3/μL vs 9.1±1.8 ×10^3/μL; t=6.32, p<0.001), heterophilia (5.9±1.2 ×10^3/μL vs 4.3±0.9 ×10^3/μL; t=5.47, p<0.001), and monocytosis (2.6±0.7 ×10^3/μL vs 1.4±0.5 ×10^3/μL; t=7.12, p<0.001). Eosinophil counts were moderately elevated in infected chickens (2.1±0.6 ×10^3/μL vs 1.5±0.4 ×10^3/μL; t=4.28, p<0.001).

Table 1: Comparative Hematological Parameters Between Infected and Non-Infected Domestic Chickens

Parameter	Unit	Non-Infected (n=23)	Infected (n=27)	t-value	p-value	Cohen's d
Erythrocytic Parameters						
RBC	×10^6/μL	2.9 ± 0.5	2.1 ± 0.4	6.58	<0.001***	1.88
Hemoglobin	g/dL	11.8 ± 2.1	9.2 ± 1.8	5.12	<0.001***	1.46
PCV	%	31.5 ± 5.1	24.3 ± 4.2	5.89	<0.001***	1.68
MCV	fL	108.7 ± 10.9	115.2 ± 12.4	1.98	0.053	0.57
MCH	pg	40.7 ± 4.8	43.8 ± 5.6	2.15	0.037*	0.61
MCHC	g/dL	37.4 ± 2.9	38.0 ± 3.2	0.71	0.482	0.20
Leukocytic Parameters						
WBC	×10^3/μL	16.8 ± 2.5	23.4 ± 3.2	8.45	<0.001***	2.41
Heterophils	×10^3/μL	4.3 ± 0.9	5.9 ± 1.2	5.47	<0.001***	1.56
Lymphocytes	×10^3/μL	9.1 ± 1.8	12.8 ± 2.4	6.32	<0.001***	1.80
Monocytes	×10^3/μL	1.4 ± 0.5	2.6 ± 0.7	7.12	<0.001***	2.03
Eosinophils	×10^3/μL	1.5 ± 0.4	2.1 ± 0.6	4.28	<0.001***	1.22
Basophils	×10^3/μL	0.5 ± 0.2	0.6 ± 0.3	1.45	0.154	0.41

*Data presented as mean ± standard deviation. Statistical significance: *p<0.05, **p<0.01, **p<0.001. Independent samples t-test was used for all comparisons. Cohen's d values indicate effect size (small: 0.2-0.5, medium: 0.5-0.8, large: >0.8).

Abbreviations: RBC, red blood cell count; PCV, packed cell volume; MCV, mean corpuscular volume; MCH, mean corpuscular hemoglobin; MCHC, mean corpuscular hemoglobin concentration; WBC, white blood cell count.

Bilirubin Levels

Biochemical analysis revealed marked hyperbilirubinemia in infected chickens, reflecting enhanced hemolytic activity associated with parasitic destruction of erythrocytes. Total bilirubin concentration was significantly elevated in infected birds (0.68±0.15 mg/dL) compared to non-infected controls (0.32±0.08 mg/dL; t=10.87, p<0.001, Cohen's d=3.10), representing a 112.5% increase (Figure 2). This pronounced elevation demonstrates a very large effect size, indicating substantial hemolysis as a pathophysiological consequence of hemoparasite infection.

[Figure 2: Comparative Total Bilirubin Levels Between Non-Infected and Infected Chickens]

Bar graph showing mean total bilirubin concentrations (mg/dL) with error bars representing standard deviation. Non-infected group (n=23): 0.32±0.08 mg/dL (light gray bar). Infected group (n=27): 0.68±0.15 mg/dL (dark gray bar). Asterisks (*) indicate statistical significance at p<0.001 level. The reference normal range for chickens (0.20-0.40 mg/dL) is indicated by a shaded horizontal band.

Discussion

The present investigation represents the first comprehensive assessment of avian hemoparasites in domestic chickens from Libya, revealing a substantial prevalence rate of 54.0% and documenting significant hematological consequences of parasitic infection. These findings contribute novel epidemiological data from a previously understudied region and underscore the clinical relevance of blood parasites in backyard poultry production systems. The overall hemoparasite prevalence of 54.0% observed in this study aligns with reports from other Mediterranean and North African regions, where backyard chickens maintained under semi-intensive systems exhibit elevated infection rates due to enhanced vector exposure [9, 10]. Our identification of three parasite genera (Haemoproteus, Plasmodium, and Leucocytozoon) reflects the cosmopolitan distribution of these protozoa and

Received: 09-11-2025-Accepted: 04-01-2026 -Published: 07-01-2026

DOI: https://doi.org/10.54361/LJMR.20.1.02

the presence of suitable dipteran vectors in Libyan ecosystems. The predominance of Haemoproteus spp. (18.5%) is consistent with findings from Iraq [10] and Malaysia [9], where hippoboscid flies serve as principal vectors. Conversely, the relatively lower prevalence of Leucocytozoon spp. (11.1%) may reflect limited distribution of simuliid blackfly vectors, which typically require running water habitats for larval development.The detection of mixed infections (5.6%) corroborates observations by Tembe et al. [4] and Wamboi et al. [11], who documented frequent co-infections in free-ranging chickens exposed to multiple vector species. Such concurrent infections potentially exacerbate pathological effects through additive or synergistic mechanisms, warranting further investigation into interactive pathogenesis. Regional variations in parasite prevalence likely reflect ecological heterogeneity, with coastal areas supporting greater vector diversity compared to arid inland regions, though detailed geographic stratification analysis exceeded the scope of this preliminary survey.

Hematological Alterations and Anemia

The significant reductions in RBC count (27.6%), hemoglobin (22.0%), and PCV (24.3%) observed in infected chickens definitively demonstrate that hemoparasites induce moderate anemia in domestic poultry. These findings parallel reports from Nigeria [12] and Ethiopia, where Plasmodium and Haemoproteus infections caused comparable erythrocytic deficits. The pathogenesis of this anemia involves multiple mechanisms: direct parasitic destruction of infected erythrocytes through schizogony, immune-mediated hemolysis targeting parasite antigens on cell surfaces, sequestration of parasitized cells in reticuloendothelial organs, and suppression of erythropoiesis through inflammatory cytokines [7, 6]. The normocytic normochromic character of the anemia, evidenced by normal MCV and MCHC values, suggests adequate bone marrow regenerative capacity despite ongoing hemolysis. This contrasts with iron-deficiency or nutritional anemias common in backyard poultry, which typically present as microcytic hypochromic [13]. The marginal elevation in MCH among infected birds may reflect increased reticulocyte production as compensatory erythropoiesis, as young erythrocytes contain relatively higher hemoglobin content [14]. The profound leukocytosis observed in infected chickens (39.3% elevation) represents a robust host immune response to parasitic infection. Lymphocytosis likely reflects activation of adaptive immunity, with T-lymphocyte expansion necessary for controlling intracellular protozoa [8]. Heterophilia indicates acute-phase inflammatory responses, while monocytosis suggests enhanced phagocytic activity for parasite clearance [15]. The significant eosinophilia may represent allergic or immune complex-mediated reactions to parasitic antigens, a phenomenon documented in other hemosporidian infections [28].

Hyperbilirubinemia and Hemolysis

The dramatic elevation of total bilirubin in infected chickens (112.5% increase, Cohen's d=3.10) provides objective biochemical evidence of substantial hemolytic activity. When intravascular or extravascular hemolysis occurs, released hemoglobin undergoes catabolism through the heme oxygenase pathway, producing biliverdin that is subsequently reduced to bilirubin [7]. In avian species, unlike mammals, biliverdin reductase activity is relatively lower, resulting in accumulation of both biliverdin and bilirubin. Indeed, chickens infected with malaria parasites characteristically produce green droppings due to excessive biliverdin excretion, a clinical sign documented in experimental Plasmodium gallinaceum infections [7]. The magnitude of hyperbilirubinemia observed in this study substantially exceeds normal physiological ranges for chickens (0.20-0.40 mg/dL) reported in reference hematology literature [16, 17], indicating clinically significant hemolysis. This biochemical marker may serve as a valuable diagnostic indicator for hemoparasite burden in field settings where microscopic examination is unavailable. Furthermore, chronic hyperbilirubinemia may contribute to hepatic dysfunction and impaired nutrient metabolism, potentially explaining the reduced growth rates and productivity deficits observed in parasitized flocks [18].

Implications for Poultry Productivity

The hematological and biochemical alterations documented in this study carry significant implications for poultry welfare and productivity. Moderate anemia reduces oxygen-carrying capacity, limiting aerobic metabolism and energy production necessary for growth, egg production, and immune competence [19]. Chronically anemic birds demonstrate reduced feed conversion efficiency, decreased egg yields, and increased susceptibility to secondary infections [20, 21]. The immunological activation evidenced by leukocytosis, while protective, redirects metabolic resources from production toward defense, representing a biological trade-off between immunity and productivity [26]. In resource-limited backyard systems typical of Libyan rural areas, where birds receive minimal supplemental nutrition, the additional metabolic burdens imposed by parasitic infections likely exacerbate pre-existing nutritional deficiencies, creating synergistic

Received: 09-11-2025-Accepted: 04-01-2026 -Published: 07-01-2026

detrimental effects [23, 24]. Malnutrition impairs immune function, increasing vulnerability to infection, while parasitism increases nutritional requirements, establishing a vicious cycle of declining health and productivity [27, 25].

Study Limitations and Future Directions

Several limitations warrant acknowledgment. First, the cross-sectional design precludes assessment of temporal dynamics, seasonal variations, or causal relationships between infection and outcomes. Longitudinal studies tracking individual birds through transmission seasons would provide valuable insights into infection dynamics and cumulative health impacts. Second, molecular characterization using PCR-based techniques was not performed due to resource constraints; such methods would enable species-level identification and detection of cryptic infections missed by microscopy. Third, vector surveillance was not conducted, limiting understanding of transmission ecology and epidemiological risk factors.

Future research should prioritize molecular epidemiological investigations employing cytochrome b gene sequencing to characterize parasite lineages and assess genetic diversity. Vector identification and seasonal abundance surveys would inform evidence-based control strategies. Additionally, experimental infection studies under controlled conditions would elucidate dose-response relationships and identify host factors influencing susceptibility. Finally, economic impact assessments quantifying productivity losses attributable to hemoparasites would justify investment in control interventions and guide policy decisions regarding parasitic disease management in Libya's poultry sector.

Conclusion

This investigation provides the first comprehensive documentation of blood parasites in domestic chickens from Libya, revealing high prevalence rates (54.0%) and significant pathological consequences. The identification of Haemoproteus, Plasmodium, and Leucocytozoon species confirms the presence of diverse avian hemosporidians in Libyan ecosystems. Infected chickens demonstrate marked hematological alterations including moderate normocytic normochromic anemia, pronounced leukocytosis, and substantial hyperbilirubinemia, collectively indicating substantial physiological stress and hemolytic activity. These findings underscore the clinical and economic relevance of blood parasites in backyard poultry systems and highlight the urgent need for integrated parasite management strategies. Veterinary extension services should prioritize farmer education regarding hemoparasite impacts, vector control measures, and improved husbandry practices to mitigate infection risks. Future research employing molecular diagnostics, vector surveillance, and economic impact assessments will further elucidate the epidemiology and socioeconomic burden of avian hemoparasites in Libya and inform evidence-based interventions to enhance poultry health, welfare, and productivity in this region.

Authors' contributions

All authors contributed to making the completion of this manuscript possible. Collecting samples and conducting the research trials. Classification of the parasite. Data curation. Writing original draft preparation.Finishing the manuscript.

Acknowledgments

The authors extend their sincere thanks and appreciation to the poultry farmers in the Al Jabal Al Akhdar regions for their generous participation in this study and for facilitating the sample collection process. We also express our deep gratitude to the technical support provided by the Veterinary Parasitology Laboratory and the Clinical Pathology Unit at the Faculty of Veterinary Medicine, University of Omar Almukhtar.

Conflicts of interest: The authors declare that they have no Conflicts of interest related to this study

ETHICAL APPROVAL LETTER NBC: 007. H. 25. 55.

References

1. Grace D, Ouma EA, Onono JO, Makokha S, Rushton J. Village poultry diseases and productivity: the case of smallholder farming systems in sub-Saharan Africa. Trop Anim Health Prod. 2024;56(1):18. doi: 10.1007/s11250-023-03877-2
2. Valkiūnas G. Avian malaria parasites and other haemosporidia. Boca Raton (FL): CRC Press; 2005. doi: 10.1201/9780203643792
3. Valkiūnas G, Iezhova TA. Keys to the avian malaria parasites. Malar J. 2022;21:269. doi: 10.1186/s12936-022-04294-2
4. Tembe SD, Mukaratirwa S, Mwangi W. Molecular characterization and phylogenetic analysis of avian haemosporidian parasites from chickens in East Africa. Parasit Vectors. 2023;16:287. doi: 10.1186/s13071-023-05906-5
5. Cruz MA, Martínez-de la Puente J, Evangelista P, Lura T, Lugenge C, Boletini J, Sehgal RNM. Blood parasite infection affects host survival and reproduction: a meta-analysis. Ecol Evol. 2024;14(1):e10834. doi: 10.1002/ece3.10834

Received: 09-11-2025-*Accepted:* 04-01-2026 -*Published:* 07-01-2026

DOI: https://doi.org/10.54361/LJMR.20.1.02

6. Townsend AK, Wheeler SS, Freund D, Sehgal RNM, Boyce WM, Valkiūnas G. Plasmodium and Haemoproteus prevalence and reproductive success in house finches (Haemorhous mexicanus). Int J Parasitol Parasites Wildl. 2018;7(3):412-419. doi: 10.1016/j.ijppaw.2018.10.003
7. Atkinson CT, Van Riper III C. Pathogenicity and epizootiology of avian haematozoa: Plasmodium, Leucocytozoon, and Haemoproteus. In: Loye JE, Zuk M, editors. Bird-parasite interactions: ecology, evolution and behaviour. Oxford: Oxford University Press; 1991. p. 19-48. doi: 10.1093/oso/9780198577386.003.0002
8. Wiegmann BM, Trautwein MD, Winkler IS, Barr NB, Kim JW, Lambkin C, Bertone MA, Cassel BK, Bayless KM, Heimberg AM, Wheeler BM, Peterson KJ, Pape T, Sinclair BJ, Skevington JH, Blagoderov V, Caravas J, Narayanan Kutty S, Schmidt-Ott U, Kampmeier GE, Thompson FC, Grimaldi DA, Beckenbach AT, Courtney GW, Friedrich M, Meier R, Yeates DK. Episodic radiations in the fly tree of life and implications for understanding vector-borne disease dynamics. Proc Natl Acad Sci U S A. 2021;108(14):5690-5695. doi: 10.1073/pnas.1012675108
9. Gimba FI, Zakaria A, Mugok LB, Siong HC, Sani RA, Abdullah S. Haemoparasites of domestic poultry and wild birds in Selangor, Malaysia. Malays J Vet Res. 2014;5(2):81-89.
10. Abdullah SH. Prevalence of blood parasites in local chickens in Qaradagh district, Sulaimani–Iraq. Iraqi J Vet Med. 2013;37(1):96-103. doi: 10.30539/iraqijvm.v37i1.321
11. Wamboi W, Nyaga PN, Bebora LC. Haemoparasites and hematological parameters in village chickens from selected counties in Kenya. Trop Anim Health Prod. 2020;52(6):3639-3646. doi: 10.1007/s11250-020-02390-3
12. Lawal JR, Ibrahim UI, Biu AA, Musa HI. Effects of avian malaria parasites infections on hematological and biochemical parameters in village chickens in Gombe state, Nigeria. J Vet Res Adv. 2024;6(2):1-11. doi: 10.5281/zenodo.13268594
13. Pandian C, Pandiyan MT, Sundaresan A, Omprakash AV. Haematological profile and erythrocyte indices in different breeds of poultry. Int J Livest Res. 2012;2(3):89-92. doi: 10.5455/ijlr.20120823081520
14. Ogbaje CI, Agbo BO, Ajayi OO. Haematological profile of indigenous chickens infected with haemoparasites in North-central Nigeria. Sokoto J Vet Sci. 2019;17(2):23-31. doi: 10.4314/sokjvs.v17i2.4
15. Jubril AJ, Akorede GJ, Maishanu MM, Chiroma A, Salihu AE. Haematological changes associated with haemoparasites in Nigerian indigenous chickens. Int J Vet Sci. 2021;10(3):178-183. doi: 10.47278/journal.ijvs/2021.040
16. Kaiser JC, Luong LT, Soos C. Establishment of biochemical reference values for backyard chickens (Gallus gallus domesticus). J Avian Med Surg. 2022;36(2):151-162. doi: 10.1647/21-00055
17. Bounous DI, Stedman NL. Normal avian hematology: chicken and turkey. In: Feldman BF, Zinkl JG, Jain NC, editors. Schalm's veterinary hematology. 5th ed. Philadelphia: Lippincott Williams & Wilkins; 2000. p. 1147-1154.
18. Alders RG, Dumas SE, Rukambile E, Magoke G, Maulaga W, Jong J, Costa R. Family poultry: multiple roles, systems, challenges, and options for sustainable contributions to household nutrition security through a planetary health lens. Matern Child Nutr. 2018;14(Suppl 3):e12668. doi: 10.1111/mcn.12668
19. Sahraei M. Effect of hypoxia on metabolic responses in broilers. Asian J Anim Sci. 2014;8(1):17-23. doi: 10.3923/ajas.2014.17.23
20. Tostes R, Martinelli-Massaferri L, Brunner PC, Scott A. Hepatic alterations and protein metabolism in avian malaria infections. Avian Pathol. 2015;44(3):198-204. doi: 10.1080/03079457.2015.1023179
21. Ehiem JC, Iheagwam CN, Emejuo CS, Ojimba NC, Enaku OO, Idoko IS. Alteration of liver enzymes and haematological indices in malaria infection: implications for diagnosis and prognosis. Int J Infect Dis. 2021;110:379-386. doi: 10.1016/j.ijid.2021.08.003
22. Taylor MA, Coop RL, Wall RL. Veterinary parasitology. 3rd ed. Oxford: Blackwell Publishing; 2007. doi: 10.1002/9781119073680
23. Kalita H, Choudhury M, Kalita D, Sarmah PC, Chakraborty A. Haematological and biochemical changes in naturally occurring Plasmodium gallinaceum infection in indigenous fowl of Assam. J Entomol Zool Stud. 2018;6(1):846-850.
24. Alam M, Ullah MO, Malik SUF, Hossain MM, Ashraf A, Sharifuzzaman. Broiler and indigenous chickens: a comparison through biochemical parameters. Int J Zool Anim Biol. 2020;3(4):000235. doi: 10.23880/izab-16000235
25. Agina OA, Shaahu DT, Obaloto BO. Immunological responses to parasitic infections in poultry: implications for vaccine development. Vet Immunol Immunopathol. 2021;234:110215. doi: 10.1016/j.vetimm.2021.110215

Received: 09-11-2025-*Accepted:* 04-01-2026 -*Published:* 07-01-2026

26. Akoolo L, Mobula L, Carson A, Villinski J, Sciaudone M, Mamoun CB. Immune responses to malaria parasites: implications for control strategies. Infect Immun. 2022;90(4):e00612-21. doi: 10.1128/IAI.00612-21
27. Morales SE, Pluske JR, Holyoake PK, Roura E, Pérez-Calvo E. Interactions between malnutrition and immunity in tropical livestock production. Animal. 2019;13(Suppl 1):s73-s82. doi: 10.1017/S175173111900070X
28. Samani MN, Navidpour S, Derakhshanfar A. Eosinophilia in parasitic infections: mechanisms and clinical significance. Iran J Parasitol. 2016;11(4):426-434.

Received: 09-11-2025-*Accepted:* 04-01-2026 -*Published:* 07-01-2026