

## Atypical intramuscular location of primary hydatid cyst

Hussein Mohamed Lameir<sup>1</sup>. (MD), And Mira, Ranim R<sup>2</sup>. (MS),

1-Arab Board of Radiology, European Society of Radiology membership, Head of Radiology Department at Zawia Teaching Hospital, Zawia, Libya.

2- Member of American Association of Clinical Chemistry (AACC), Member of International Osteoporosis Foundation.

### Abstract

Cystic echinococcosis is globally distributed and found in every continent except Antarctica. The disease often starts without symptoms and this may last for years. The symptoms and signs that occur depend on the cyst's location and size. Hydatid cyst involves all human parts and most common affected organs are liver and lungs but the incidence of unusual site is only about 8-10%. Even in regions where echinococcosis is endemic such as Libya, hydatidosis of cervical muscular region is extremely rare. In this study, we present exceptionally rare case with an unusual localization of primary hydatid cyst in the muscle of the neck with atypical presentation, skeletal muscle echinococcosis should be considered in the differential diagnosis of neck masses, especially in endemic countries. A detailed history taking and MRI imaging are essential for accurate surgical planning.

Keywords

Hydatid cyst; Cervical region; Neck mass; Skeletal muscle; Unusual localization; Atypical presentation>

<https://doi.org/10.54361/ljmr.11.1.07>

### Introduction

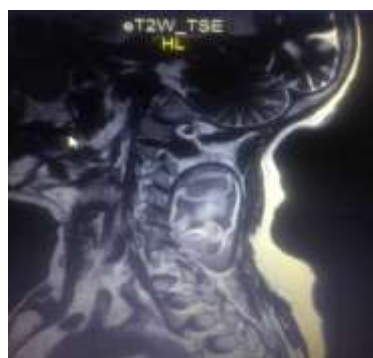
Human infestation with Hydatid cyst is caused by the larval stage of *Echinococcus granulosus* and is cosmopolitan in distribution in north and northwestern China, parts of South America, East Africa, Australia, Central Asia, Russia and the Mediterranean regions including North Africa . Cystic echinococcosis is also endemic in parts of Western Europe and southern USA. [1] In endemic regions, human incidence rates for cystic echinococcosis can reach more than 50 per 100 000 person-years. Humans are infected through ingestion of parasite eggs in contaminated food, water or soil, or through direct contact with animal hosts. [2] Until now, only a few cases of hydatid cyst have been reported in the head and

neck, an unusual location [3] Among all the reported cases musculoskeletal or soft tissue hydatidosis accounts for about 0.5% 5% of all echinococcal infections in endemic areas [4], and is almost always secondary to the hepatic or pulmonary disease, although there can be involvement of almost all organs and systems. Muscle hydatid disease lacks a typical clinical appearance, we highlight the fact that this disease should be suspected in cystic lesions involving any organ in the body, especially in endemic areas like Libya. In this paper we describe an unusual case of cystic echinococcosis which presented as cervical neck mass . MRI easily clarified the cyst as primary Hydatid cyst while cystectomy is the effective method of treatment and mangement.

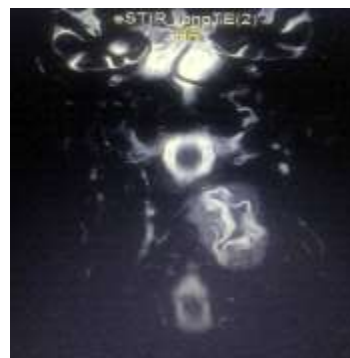
A 75 years old woman presented to our hospital with more than one year history of lump growing on the back of her neck. Physical examination, there was a uniform, smoothly outlined mass with a diameter of 8x5 cm on the left cervical region of the back of the neck. The mass did not reveal any findings of erythema, ecchymosis or regional lymphadenopathy. There was no history of trauma, fever or weight loss. Ultrasonographic examination of the mass showed a homogenous and anechoic thin walled cystic mass with serpiginous membrane floating inside it. Magnetic resonance imaging (MRI) was done and

which gradually increased in size without any pain. Upon

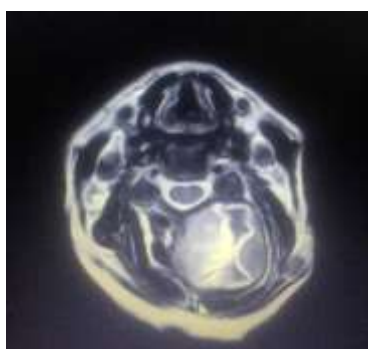
revealed around 7,5x5x4 cm mass of mixed intensity T1WI with central necrosis, hypointense T2WI with serpiginous inner membrane and hypointense thin wall, the mass centered in the left deep cervical muscle posterior to vertebral body (semispinalis cervicis, semispinalis capitis and multifidus muscles) and from the level of C2 to level of D1 vertebral body. The MRI is the most helpful technique for diagnosing hydatid cyst disease.



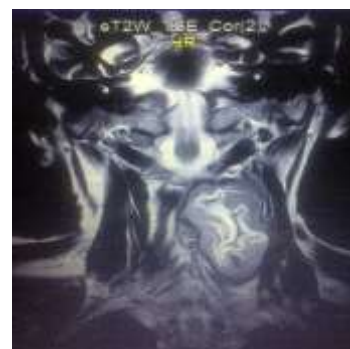T2WI sagittal image



STIR coronal image



T2WI axial image



T2WI coronal image

## Discussion

Hydatid disease is a parasitic infestation which can involve any part of the body[5]. There are reports mentioning hydatid disease involving unusual sites like the spleen, kidney, heart, bone, and involvement in the same patient.[7] However, in the absence of multiple organ involvement, the diagnosis may be rather hard to be identified. The reported soft tissue hydatid cysts are usually secondary to liver or lung involvement, the primary hydatidosis of skeletal muscle is therefore rare, with reported prevalence of 0.5–5%[4], because the cyst uses oxygen for growth and muscles usually contain lactic acids.[7] Soft tissue hydatid disease is uncommon, even in endemic areas.[8] Cystic echinococcosis [CE] grows slowly, like benign tumor. The contractile nature of the muscles nearly inhibits the growth process of the cysts.[9,10] HCs have been reported in the muscles of the neck, trunk and the root of the limbs and that can be explained with the increased vascularization and the decreased muscular activity in these regions[11,12,13]. The main clinical presentation of muscular HCs is palpable painless slowly growing mass[14]. Echinococcosis is diagnosed essentially by the patient's history, physical examination findings, radiologic imaging modalities, aspiration and serological tests. Radiologic imaging modalities generally include ultrasound, computerized tomography (CT) and MRI [15] In the current report,

cranium but involvement of soft tissue comprises less than 3% of all hydatidosis [6]. Hydatid cyst [HC] in an unusual location may be recognized easily, if there is multiorgan Primary CE of the neck musculature are usually solitary and unilocular or multilocular. In our case, the lesion was occupying nearly the entire posterior aspect of the neck, specifically located in the intramuscular region of the cervical areas as intra macular mass lesion with inner detached germinal layer. MRI can adequately demonstrate most features of HC other than calcifications. In addition, MRI is superior to US and CT, depicting an exact compromise of adjacent soft tissues. MRI typically shows a thin, low intensity rim, probably representing the pericyst which is rich in collagen and is generated by the host. A low-intensity rim (rim sign), more evident on T2-weighted images, has been described as a characteristic sign in muscular CE. Differential diagnosis of the muscular HC includes abscesses, chronic hematomas, lymphangiomas, synovial cysts, and necrotic malignant soft tissue tumors.[14]. We conclude that Hydatid cyst can affect any organ in the body from head to toe, and a high suspicion of this disease is considered in endemic regions. Furthermore, we suggest that medical treatment should be given in the pre-operative as well as in the post-operative period.

## References

- 1- Gemmell M A, Lawson J R, Roberts M G. Towards global control of cystic and alveolar hydatid diseases. *Parasitol Today* 1987;3:144–151.
- 2- Echinococcosis, WHO
- 3- Katılmış H, Oztürkcan S, Ozdemir I, Adadan Güvenç I, Ozturan S. Primary hydatid cyst of the neck. *Am J Otolaryngol.* 2007 May-Jun; 28(3):205-7. S Sachar, S Goyal, S Goyal, S Sangwan. Uncommon Locations and Presentations of Hydatid Cyst. *Ann Med Health Sci Res.* 2014 May-Jun; 4(3): 447–452. doi: 10.4103/2141-9248.133476
- 4- Ismail İyener, Özgür Sogut, Muhammet E Guldur, Rustu Kose, Halil Kaya, Ferhat Bozkusa. Primary Hydatid Cyst: An Unusual Cause of a Mass in the Supraclavicular Region of the Neck. *J Clin Med Res.* 2011 Feb; 3(1): 52–54. 2011 Feb 12. doi: 10.4021.
- 5- Polat P, Kantarci M, Alper F, Suma S, Koruyucu MB, Okur A. Hydatid disease from head to toe. *Radiographics.* 2003 Mar-Apr; 23(2):475-94; quiz 536-7.
- 6- Cangiotti L, Muiesan P, Begni A, de Cesare V, Pouchè A, Giulini SM, Tiberio G. Unusual localizations of hydatid disease: a 18 year experience. *G Chir.* 1994 Mar; 15(3):83-6.
- 7- Tatari H, Baran O, Sanlidag T, et al. Primary intramuscular hydatidosis of supraspinatus muscle. *Arch Orthop Trauma Surg.* 2001; 121: 93–4.
- 8- S Sachar, S Goyal, S Goyal, S Sangwan. Uncommon Locations and Presentations of Hydatid Cyst. *Ann Med Health Sci Res.* 2014 May-Jun; 4(3): 447–452. doi: 10.4103/2141-9248.133476
- 9- Keskin D, Ezirmik N, Karsan O et al. Primary hydatidosis of the gracilis muscle in a girl. *J Int Med Res.* 2002; 30: 449–51.
- 10- Kocakusak A, Koyuncu A, Arıkan S, et al. Primary Hydatid Cyst of Vastus Lateralis Muscle. *Acta Chir Belg.* 2004; 104: 471–2
- 11- Garcia-Diez AI, Ros Mendoza LH, Villacampa VM, et al. MRI evaluation of soft tissue hydatid disease. *Eur Radiol.* 2000; 10: 462–6.
- 12- Comert RB, Aydingoz U, Ucaner A, et al. Waterlily sign on MR imaging of primary intramuscular hydatidosis of sartorius muscle. *Skeletal Radiol.* 2003; 32: 420–3.
- 13- Joshi SG, Deodhar SD, Kamat MH. Primary intermuscular hydatid cyst. a case report. *J Postgrad Med.* 1963; 28: 135–7.
- 14- Mehmet Haydar Atalar, Levent Cankorkmaz, Gökhan Köylüoğlu, İsmail Şalk. Imaging Characteristics of Three Primary Muscular Hydatid Cyst Cases with Various Patterns. *Kafkas J Med Sci* 2012; 2(2):74–77 • doi: 10.5505/kjms.2012.76486
- 15- Dirican A, Unal B, Kayaalp C, Kirimlioglu V. Subcutaneous hydatid cysts occurring in the palm and the thigh: two case reports. *J Med Case Rep.* 2008 Aug 13; 2():273.