

Sarcomatoid urothelial carcinoma in a bladder diverticulum: first report of an unusual case.

<https://doi.org/10.54361/ljmr.11.1.05>

L. S. Elbarghati & L. M. Azzouz, W.M Alsarraj
Medical School, Tripoli University, Tripoli, Libya

Address for correspondence: Dr Laila Elbarghati Tripoli University Tripoli, Libya

Email: bargati@hotmail.com

Abstract

70-year-old Libyan man presented with abdominal distension and gross hematuria. Cystoscopy showed diverticulum in urinary bladder with tumor arising from its lateral wall. The tumor was composed of conventional urothelial carcinoma with sarcomatoid features. The clinical presentation and management are being discussed.

Key words: Urinary bladder, Sarcomatoid urothelial carcinoma

Introduction

Sarcomatoid variant of urothelial carcinoma of the urinary bladder is an uncommon neoplasm with biphasic morphology exhibiting both epithelial and sarcomatoid components. This variant is associated with inferior outcome in comparison with conventional urothelial carcinoma as it is typically present at an advanced stage and is associated with a poor prognosis [1]. Although some investigators favor the use of the term carcinosarcoma, the current recommendation by the World Health Organization is to use the term sarcomatoid carcinoma for this entity [2]. It is a rare variant which accounts for approximately 0.3% of all urothelial tumors [3]. The exact histogenesis of sarcomatoid urothelial carcinoma has not been clearly elucidated. Two opposing theories have been proposed to explain the origin of these morphologically diverse tumours. The monoclonal theory (divergent hypothesis) proposes that both carcinomatous and sarcomatous elements are derived from a single pluripotential stem cell that subsequently develops divergent differentiation along separate epithelial and mesenchymal pathways. The multiclonal theory (convergence hypothesis) regards sarcomatoid carcinoma as a collision tumour composed of the derivatives of two or more stem cells of separate epithelial and mesenchymal origin [4]. Therefore, its pathogenesis is still a matter of controversy. This tumor has a median survival of 10 months. Radical surgery with adjuvant radiation therapy to eradicate microscopic disease is the traditional standard treatment for most sarcomas [5].

Case presentation

Patient presented with dyspnea, abdominal swelling and difficult micturation for 20 days. Dyspnea was aggravated by eating and mild exertion. Abdominal distension increased gradually and associated with hematuria and urine retention. The patient was chronic smoker for 40 years and hypertensive one year ago. On general examination he had weight loss with pitting edema in

the lower limbs and distended veins. Abdominal examination showed huge distended abdomen, flat umbilicus and visible superficial veins, shifting dullness and fluid thrill were positive. His investigations showed low haemoglobin, high urea and raised parathyroid hormone. Ultrasound abdomen and pelvis revealed hydronephrosis of left kidney and increased echogenicity in the right kidney with mild dilated calyceal system. Cystoscopy showed trabeculated urinary bladder wall with a diverticulum arising from the lateral wall cm. A tumor mass arising from the lateral wall measured 9x7 was also seen. The prostate was enlarged mainly in the median lobe. Two months prior to the surgery cystoscopy and punch biopsy was done which showed squamous metaplasia with mild dysplasia and calcification. At the same time transurethral prostatic resection was done for benign prostatic hyperplasia. Under general anesthesia and aseptic technique the abdomen was opened in layers through mid-line incision. Partial cystectomy, diverticulectomy and left nephrectomy were done. Good hemostasis, urinary bladder was closed, R-vaj drain and urethral catheter were inserted. Specimen received into 2 containers, one contained disfigured dilated urinary bladder already opened measured 20x15x0.8 cm with a diverticulum showed papillary hemorrhagic growth measured 8x5x3 cm. The other container showed enlarged cystic kidney measured 13x6x4 cm with dilated pelvis and dilated ureter measured 23 cm (Figure 1). Microscopic examination from the submitted tumor at the diverticulum showed diffuse infiltrating tumor composed of two component, first component showed malignant transitional carcinoma arranged in solid structures infiltrating the full thickness of the bladder wall. The second component showed sarcoma like appearance, composed of spindle cells having large pleomorphic hyperchromatic nuclei, prominent nucleoli with deeply stained eosinophilic cytoplasm with high mitotic activity. These cells were admixed with osteoclast like giant cells (Figure 1). Extensive areas of necrosis and haemorrhage were seen. No perivesicle fat seen. The section from submitted kidney and ureter showed multiple cystic lesions lined by flattened epithelium. Glomeruli showed hypercellularity thick basement membrane. Tubules showed red blood cells and hyaline casts, interstitium was infiltrated by lymphocytes with fibrosis and thick walled blood vessels. Ureter lined by benign transitional epithelium. Kidney and ureter were free from tumor invasion. Immunohistochemistry showed Cytokeratin (CK) and Vimentin positivity for epithelial & mesenchymal elements respectively. Epithelial membrane antigen (EMA) was positive in the epithelial component (Figure 3), whereas Desmin and α -Smooth muscle actin (α -SMA) were positive in the sarcomatous component (figures not shown). The diagnosis was sarcomatoid urothelial carcinoma, stage pT2NxMx according to TNM system. Post operative period was normal. A week after the operation the patient suddenly developed acute

cerebrovascular accident (CVA) and CT-scan for the brain showed left lacunar infarct. Then the patient dies after 2 weeks.

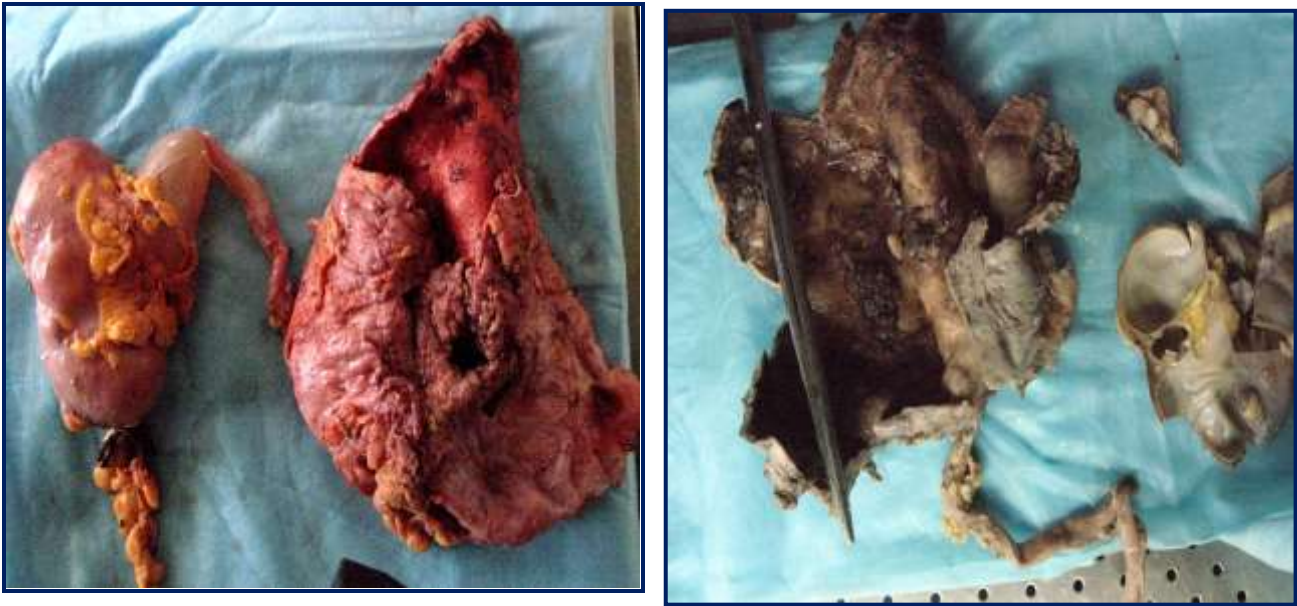


Figure 1: Gross picture of hydronephrotic kidney with already opened bladder with mass in the diverticulum.

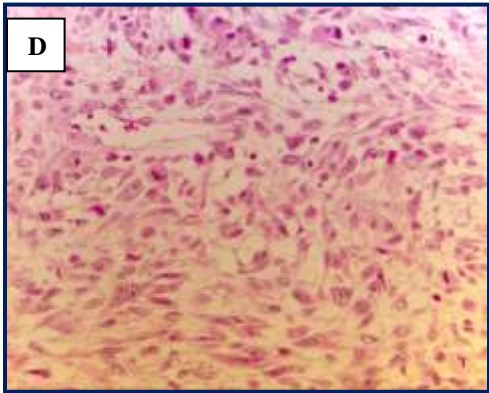
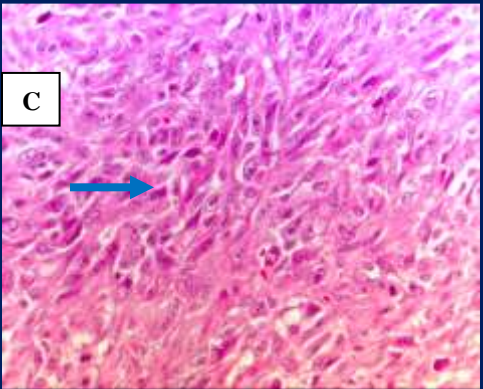
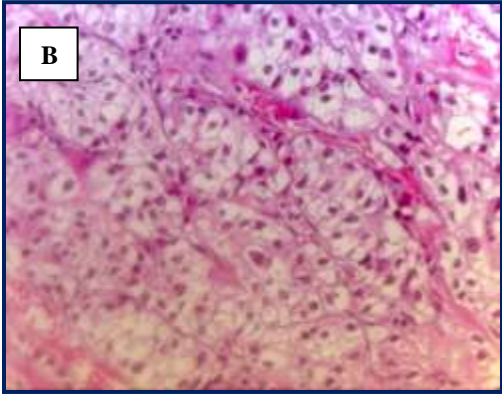
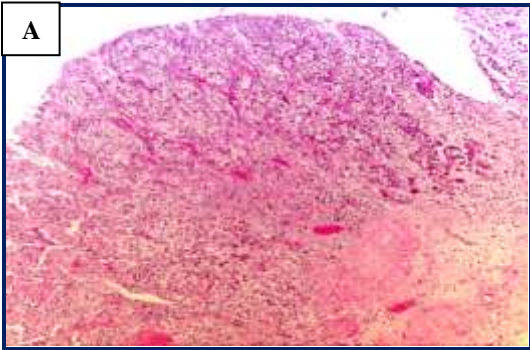


Figure 2: Histological features of sarcomatoid urothelial carcinoma. A: Nests of invasive urothelial carcinoma. B. Invasive transitional cell carcinoma. C. Sarcomatoid component consist of solid sheets of spindle neoplastic cells with multinucleated giant cells (arrow). D. Numerous mitotic figures in sarcomatoid urothelial carcinoma. (H &E stain) (A x10: B,C & D x40).

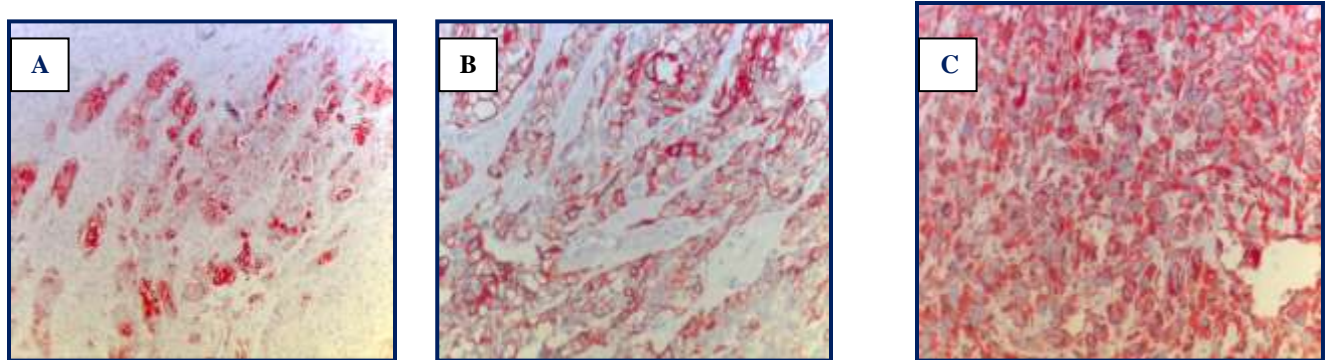


Figure 3. Immunostaining for sarcomatoid urothelial carcinoma. A: Tumor cells show strong EMA staining. B: Tumor cells show strong Cytokeratin staining. C: Tumor cells show strong & diffuse Vimentin staining (A x10: B, C x40 Immunoperoxidase).

Discussion

Sarcomatoid urothelial carcinoma of the urinary bladder is an unusual malignancy with bidirectional epithelial (carcinomatous) and mesenchymal (sarcomatous) differentiation. Patients with this neoplasm are predominantly male and most patients are between 60 and 70 years of age, they generally present with specific symptoms of lower urinary tract symptoms as hematuria as in our case [5]. Etiologic factors are largely unknown, although some believe previous radiotherapy may be a significant contributing factor [6]. The epithelial components most frequently described in sarcomatoid carcinoma include urothelial carcinoma, small-cell carcinoma, squamous carcinoma and adenocarcinoma. Chondrosarcoma, osteosarcoma, rhabdomyosarcoma, leiomyosarcoma and undifferentiated sarcoma comprise the most frequently identified mesenchymal components [7]. Armah *et al.*, 8 was reported a case of urothelial carcinoma with choriocarcinomatous element in which tumor cells were positive to human chorionic gonadotropin (HCG). The origin of this unusual lesion is controversial. Some investigators believe that it represents the collision of two separate malignant tumors occurring independently and synchronously in the same location [9, 10]. Others suggest that sarcomatoid carcinoma has a monoclonal origin with subsequent differentiation into its carcinomatoid and sarcomatoid elements. Armstrong and his colleague 2009 11 have clarified its clonal origin by analyzing the TP53 mutation status of a series of 17 sarcomatoid urothelial carcinomas using single-strand conformation polymorphism, DNA sequencing and p53 immunohistochemistry. The results suggest that despite their conspicuous divergence at the phenotypic level, the sarcomatoid and carcinomatoid elements of this uncommon tumor share a common clonal origin.

The occurrence of a tumour inside a diverticulum is relatively rare. The TCC is the commonest tumor seen in a diverticulum. About 19 cases of intradiverticular sarcomas and carcinosarcomas have been reported in the literature. Of these only two cases are of sarcomatoid carcinoma [12]. Transurethral resection and partial cystectomy carry the risk of incomplete tumour resection. Radical cystectomy with pelvic lymphadenectomy is the mainstay of treatment, although patients tend to develop local recurrence after surgery [13]. Therefore adjuvant chemotherapy and radiation should be preferred in all patients [14]. In conclusion, sarcomatoid variant of urothelial carcinoma commonly presented as high grade, advanced stage and aggressive behavior with a poor prognosis [1]. Wang *et al.*, 2010 [15] have found that only tumor stage is a significant prognostic factor for disease-specific survival. Emphasis on early detection, including identification of risk factors is needed to improve the outcome for patients with this malignancy. Urologists and pathologists should report such cases in order to contribute to the understanding of the biological behaviour of the tumour.

References

1. Wright JL, Black PC, Brown GA, et al. (2007) Differences in survival among patients with sarcomatoid carcinoma, carcinosarcoma and urothelial carcinoma of the bladder. *J Urol.* 178, 6: 2302-6.
2. Eble JN, Sauter G, Epstein JI, Sesterhenn I (2004) Pathology and genetics of tumours of the urinary system and male genital organs. IARC Press: Lyon.
3. Zhai QJ, Black J, Ayala AG, Ro JY (2007) Histologic variants of infiltrating urothelial carcinoma. *Arch Pathol Lab Med.* 131: 1244-56.
4. Sung MT, Wang M, MacLennan GT, et al. (2007) Histogenesis of sarcomatoid urothelial carcinoma of the urinary bladder: evidence for a common clonal origin with divergent differentiation *Journal of Pathology*, vol. 211, no. 4, pp. 420–430,
5. Kodzo A, Venyo G & Titi S (2014) Sarcomatoid Variant of Urothelial Carcinoma (Carcinosarcoma, Spindle Cell Carcinoma): A Review of the Literature *Urology* 9 pages. Article ID 794563.
6. Kanno J, Sakamoto A, Washizuka M, Kawai T, Kasuga T (1985) Malignant mixed mesodermal tumor of bladder occurring after radiotherapy for cervical cancer: report of a case. *J Urol.* 133, 5:854-6.
7. Lopez-Beltran A, Pacelli A, Rothenberg HJ et al. (1998) Carcinosarcoma and sarcomatoid carcinoma of the bladder: clinicopathological study of 41 cases. *J Urol.* 159, 5:1497-503.
8. Armah HB, Parwani AV (2007) Sarcomatoid urothelial carcinoma with choriocarcinomatous features: first report of an unusual case. *Urology* 70, 4: 11-14.
9. Hejtmancik JH, Klatt WW (1960) Co-existing carcinoma and sarcoma of the bladder. *J Urol.* 84:320–321.
10. Holtz F, Fox JE, Abell MR (1972) Carcinosarcoma of the urinary bladder. *Cancer* 29: 294–304.
11. Armstrong A, Wang M, Eble J et al. (2009) TP53 mutational analysis supports monoclonal origin of biphasic sarcomatoid urothelial carcinoma (carcinosarcoma) of the urinary bladder. *Modern Pathology* 22: 113–118.

12. Kishore TA, Bhat S, Albert AS, Augustine J (2005) A sarcomatoid carcinoma in a bladder diverticulum: A rare case. *Indian J Med Sci.* 59,10: 535-555.
13. Black P. C, Brown GA., and. Dinney CN et al. (2009) "The impact of variant histology on the outcome of bladder cancer treated with curative intent," *Urologic Oncology* 27, 1: 3–7.
14. Bansal A, Kumar N, Suresh C. Sharma SC (2013) Sarcomatoid variant of urothelial carcinoma of the urinary bladder. *Journal of Cancer Research and Therapeutics* 9, 4: 571-573.
15. Wang J, Wang F, LaGrange C et al. (2010) Clinical features of sarcomatoid carcinoma (carcinosarcoma) of the urinary bladder: Analysis of 221 cases. *Hindawi Publishing Corporation Sarcoma* 7 pages, Article ID 454792.